

# Earlobe Keloid: A New Treatment Protocol for Management

Anuj Kumar

Consultant Maxillofacial Surgeon, Bhagwan Mahavir Medica Superspeciality Hospital, Ranchi, Jharkhand. (Corresponding Address).  
Contact Us: www.ijohmr.com

## ABSTRACT

**Objectives:** Management of keloids has always been a subject of debate due to the lack of proper treatment guidelines. Moreover, the underlying management for keloid formation is also partially understood. Various therapies have been advocated for the management which includes surgical and nonsurgical modalities. However, there is neither any consensus nor any protocol for the management. This article aims at formulating a new treatment guideline for management of keloids. **Material and Methods:** 5 patients were treated for earlobe keloid at our maxillofacial centre. A new protocol was followed for the management. Treatment started with the injection of corticosteroid which was followed by Surgical excision. From the second postoperative day, steroid therapy was started again for a period of two months. **Result:** There was no case of any recurrence after two years of follow-up. We did not encounter any case with complications such as infection or wound dehiscence. **Conclusion:** The new treatment protocol which included combined use of corticosteroid and surgical excision is highly effective for management of earlobe keloids.

**KEYWORDS:** Keloid; Corticosteroid; Recurrence.

## INTRODUCTION

Keloids represent unorganized proliferation of fibrous tissue, which extends beyond the site of original injury and involves the adjacent peripheral tissue. The exact pathogenesis of keloid formation is largely unknown though a family history is well documented.<sup>1</sup> Other factors include an altered growth factor, immune dysfunction, sebum reaction and altered mechanics.

Earlobes are common sites for keloid formation after ear piercing, with an incidence of approximately 2.5%.<sup>2</sup>

The numerous treatments for keloids have been proposed ranging from surgical excision, steroid injection, radiation therapy, laser, silicone, and pressure therapy, among others.<sup>3</sup> This underscores how little is understood about this disease process as well as the treatment protocol.

In spite of so many treatment options, no proper protocol is available for the treatment of keloids. Moreover, very little documentation on surgical methods is available in the literature.

This article describes a new treatment protocol for management of keloid which includes a combination of surgical excision and use of corticosteroids, in both preoperative as well as postoperative period. There was no case of recurrence in our study with a follow-up period of 2 years.

## MATERIALS AND METHODS

Five female patients with a history of growth over the ear lobe were treated at our maxillofacial Centre. All the

patients gave the history of ear piercing, after which the growth started. The mean age of patients was 21 year. On clinical examination, all patients had keloid of pedunculated type.

Three patients had Type 1a type of keloid whereas in two cases it was of type 1b. The classification was done as per Chang-Park classification of earlobe keloids<sup>2</sup>. (Figure – 1)

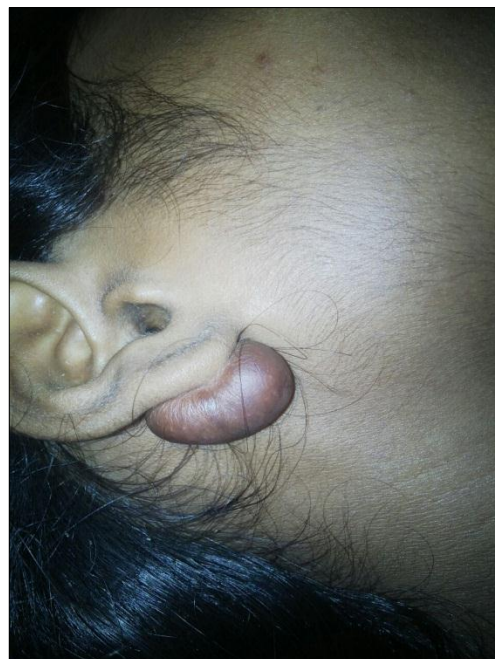


Fig 1: Ear Lobe keloid

How to cite this article:

Kumar A. Earlobe Keloid: A New Treatment Protocol for Management. *Int J Oral Health Med Res* 2016;3(1):62-64.

Occurrence rate of type 1b keloid is comparatively low and approximately around 2.4% whereas type 1a has occurrence rate of 26%.<sup>4</sup> Four patients gave a family history of keloid formation. However in one case there was no family history.

A new treatment protocol was formulated for the management of the lesion, which can be universally accepted and can reduce the rate of recurrence.

Treatment planning was divided into three stages. In the preoperative phase Intralesional triamcinolone acetonide, (Kenacort from Abbott Healthcare Pvt Ltd ) a potent anti-inflammatory hydrocortisone was injected, 10 mg per linear centimeter of a keloid. The injection was repeated after every 7 days, for a period of 1 months. 2% lignocaine was mixed along with the steroid to produce the analgesic effect. This was followed by the surgical excision of the lesion. The Lesion was excised completely with a margin of around 5 mm. After excision lateral undermining was done to relieve the tension. This was done to ensure that all the remnants are removed clearly.

Subcuticular suturing was done to avoid suture marks. Excised tissue (Figure – 2) was sent for histopathological examination.

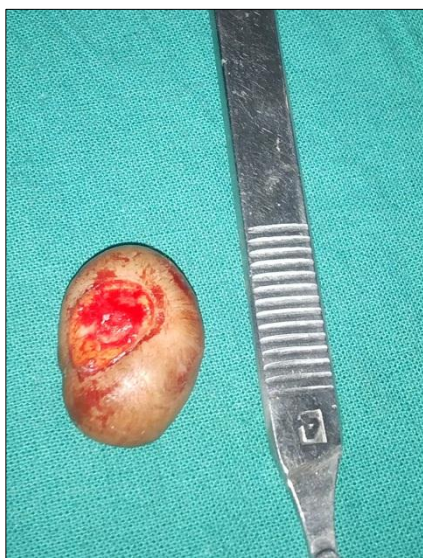

Fig 2: Excised Keloid Tissue

In the postoperative period, intralesional steroids were continued from the second day. Steroid injection of triamcinolone acetonide, 10 mg, was continued post-operatively for a further period of 2 months, repeated every week. Suture removal was done on the fifth day. In none of the cases, there was any requirement for flap advancement or any grafting material. Follow-up was done on every month.

## RESULTS

There was no sign of recurrence in any case, until two years of follow-up. In none of our case there was any postoperative complication in terms of wound dehiscence or infection. (Figure – 3,4)

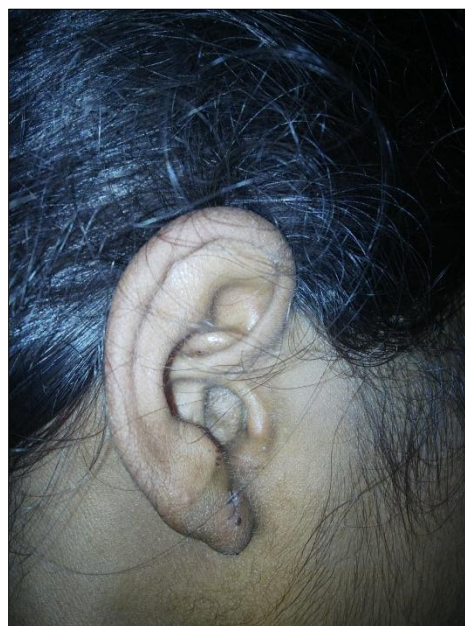


Fig 3: 1<sup>ST</sup> Follow up

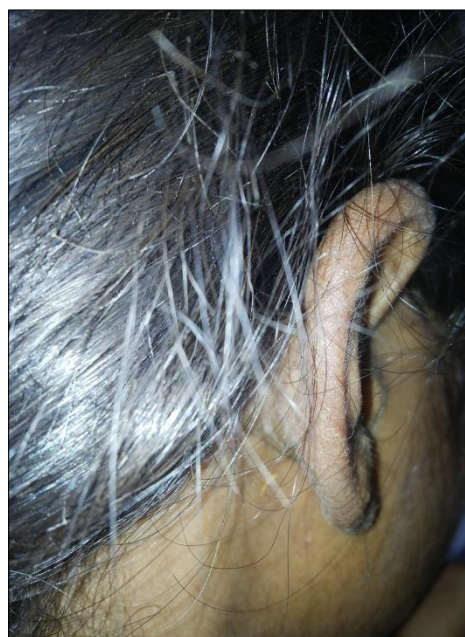

Fig 4: 1<sup>ST</sup> Follow up

Definitive treatment of ear lobe keloid has always been a surgical challenge. High incidence of the recurrence is generally associated with the surgical excision.

New treatment guidelines which include preoperative, as well as postoperative steroid administration, has shown promising result. After two years of follow-up there was no incidence of the recurrence which reinforces the use of steroids along with the surgical excision. Though steroids are associated with risk of infection, we did not encounter any such complications.

## DISCUSSION

Treatment of keloid has always been characterized by



high recurrence rate. Due to lack of any consensus on the treatment protocol, keloid present a surgical challenge with a variable and uncertain result.

Surgical excision alone is highly susceptible to recurrence which may vary from 40-100%.<sup>5-6</sup> Also, they result in faster regrowth and finally a larger keloid.<sup>7</sup>

An international Advisory Panel on scar management constituted in 2002 provided few guidelines for minor keloids<sup>6</sup>. It recommended a combination of intra lesional steroids and silicone gel sheeting. However, application of silicone gel sheet is very inconvenient and not practicable for the lesions present on the ear.

Pressure therapy has also been widely used<sup>8,9</sup> for ear keloid with recurrence rate as low as 40%. Custom made methyl methacrylate stent has also been advocated which applies uniform pressure by confinement of the soft tissue to the internal dimension of the stent.<sup>10</sup>

Radiation therapy has also been effective in reducing the recurrence rate.<sup>11-14</sup> A total dose of 10-15 Gy, using fractionated therapy is generally administered immediately after the keloid excision. However, the theoretical risk of inducing malignancy has limited the use of radiation therapy.

The combination of cryosurgery and intralesional steroid was tried in 30 patients with a partial recurrence rate of 21% and complete recurrence rate in 10%.<sup>15</sup>

Laser therapy has also been advocated but not found to be very effective for management of keloid management.<sup>16-17</sup> The carbon dioxide laser was used but yields over 50% of the result.

In our study Surgical excision is reinforced with the adjuvant corticosteroid therapy to reduce the recurrence rate. Triamcinolone inhibits the proliferation of normal and keloid fibroblasts, inhibits collagen synthesis, increases collagenase production, and reduces levels of collagenase inhibitors.

Working through fibroblast glucocorticoid receptors, steroids also induce ultrastructural changes in collagen synthesis that enhance the organization of the collagen bundles and also degenerate the characteristic keloidal collagen nodules. Adverse effects, including subcutaneous atrophy, telangiectasis, and pigment changes, occur in approximately half of all patients treated with triamcinolone but frequently resolve without intervention. In our study, we do not encountered any adverse reaction as sufficient time was give between the two dosages of injection.

Surgical excision along with lateral undermining results in improved outcome and lesser risk of recurrences. Gentle handling of the tissue and minimum tension while suturing is very important while excision to get improved result.

In none of our cases, we encountered recurrence. Strict adherence to the surgical protocol and regular follow-up is important.

## CONCLUSION

Surgical excision along with the adjuvant steroid therapy has proved to be very effective in the management of keloids.

## REFERENCES

1. Bayat A, Bock O, Mrowietz U, Ollier WE, Ferguson MW. Genetic susceptibility to keloid disease: transforming growth factor gene polymorphisms are not associated with keloid disease. *Expe Dermatology*. 2004;13 :120-24
2. Zuber TJ, DeWitt DE. Earlobe keloids. *Am Fam Physician* 1994;49:1835-41.
3. Davison, Steven P Mess, Sarah Kauffman, Lisa C. Ineffective Treatment Of Keloids With Interferon Alpha-2b. *Plastic & Reconstructive Surgery*. 117(1):247-252, January 2006.
4. Tae Hwan Park, Sang Won Seo, June Kyu Kim, Choong Hyun Chang. Earlobe Keloids: Classification According to Gross Morphology Determines Proper Surgical Approach. *Dermatol Surg* 2012;38:406-12
5. Berman B, Bieleley HC. Adjunct therapies to surgical management of keloids. *Dermatol Surg* 1996; 22: 126-130.
6. Mustoe TA, Cooter RD, Gold MH. International clinical recommendations on scar management. *Plast Reconstr Surg* 2002; 110: 560-571.
7. Niessen FB, Spauwen PH, Schalkwijk J, Kon M. On the nature of hypertrophic scars and keloids: a review. *Plast Reconstr Surg* 1999; 104: 1435-1458.
8. Brent B. The role of pressure therapy in management of earlobe keloids: preliminary report of a controlled study. *Ann Plast Surg* 1978; 1: 579-581.
9. Chrisostomidis C, Konofaos P, Chrisostomidis G, et al. Management of external ear keloids using form-pressure therapy. *Clin Exp Dermatol* 2008; 33: 273-275.
10. Kadouch, D. J., Van Der Veer, W. M., Delavary, B. M., Kerkdijk, D, Niessen, F. B.: An alternative adjuvant treatment after ear keloid excision using a custom-made methyl methacrylate stent. *Dermatologic Therapy*, 23: 686-692.
11. Levy, D. S., Salter, M. M., and Roth, R. E. Postoperative irradiation in the prevention of keloids. *A.J.R. Am. J. Roentgenol.* 127: 509, 1976.
12. Borok, T. L., Bray, M., Sinclair, I., Plafker, J., LaBirth, L., and Rollins, C. Role of ionizing irradiation for 393 keloids. *Int. J. Radiat. Oncol. Biol. Phys.*1988; 15: 865-68
13. Klumpar, D. I., Murray, J. C., and Anscher, M. Keloids treated with excision followed by radiation therapy. *J. Am. Acad. Dermatol.*1994; 31: 225-229
14. Ragoowansi, R., Cornes, P. G., Moss, A. L., and Gleees, J. P. Treatment of keloids by surgical excision and immediate postPlastic and Reconstructive Surgery • January 2006 298 operative single-fraction radiotherapy. *Plast. Reconstr. Surgery* 2003; 111: 1853-56
15. Whang KK, Park HJ, Myung KB. The Clinical Analysis of the Combination of Cryosurgery and Intralesional Corticosteroid for Keloid or Hypertrophic Scars *Korean J Dermatol* 1997; 35(3):450-457 .
16. Norris, JE. The effect of carbon dioxide laser surgery on the recurrence of keloids. *Plast. Reconstr. Surg.* 1991;87: 44-48.
17. Henderson, D. L., Cromwell, T. A., and Mes, L. G. Argon and carbon dioxide laser treatment of hypertrophic and keloid scars. *Lasers Surg. Med.*1984; 3: 271-274.

Source of Support: Nil  
Conflict of Interest: Nil